



Download Clinical Guidelines

# The American Society of Colon and Rectal Surgeons' Clinical Practice Guidelines for the Management of Pilonidal Disease

Eric K. Johnson, M.D.<sup>1</sup> • Jon D. Vogel, M.D.<sup>2</sup> • Michelle L. Cowan, M.D.<sup>2</sup>  
Daniel L. Feingold, M.D.<sup>3</sup> • Scott R. Steele, M.D., M.B.A.<sup>4</sup>

On Behalf of the Clinical Practice Guidelines Committee of the American Society of Colon and Rectal Surgeons

1 Uniformed Services University of the Health Sciences, Cleveland Clinic Foundation, Cleveland, Ohio

2 Department of Surgery, University of Colorado, Aurora, Colorado

3 Department of Surgery, New York Presbyterian Hospital, Columbia University, New York, New York

4 Department of Colon and Rectal Surgery, Cleveland Clinic Foundation, Cleveland, Ohio

The American Society of Colon and Rectal Surgeons (ASCRS) is dedicated to ensuring high-quality patient care by advancing the science, prevention, and management of disorders and diseases of the colon, rectum, and anus. The Clinical Practice Guidelines Committee is composed of Society members who are chosen because they have demonstrated expertise in the specialty of colon and rectal surgery. This committee was created to lead international efforts in defining quality care for conditions related to the colon, rectum, and anus. This is accompanied by developing Clinical Practice Guidelines based on the best available evidence. These guidelines are inclusive and not prescriptive. Their purpose is to provide information on which decisions can be made rather than to dictate a specific form of treatment. These guidelines are intended for the use of all practitioners, health care workers, and patients who desire information about the management of the conditions addressed by the topics covered in these guidelines.

It should be recognized that these guidelines should not be deemed inclusive of all proper methods of care or exclusive of methods of care reasonably directed to obtaining the same results. The ultimate judgment regarding the propriety of any specific procedure must be made by the physician in light of all of the circumstances presented by the individual patient.

**CME** Earn Continuing Medical Education credit online at [cme.lww.com](http://cme.lww.com).

**Funding/Support:** None reported.

**Financial Disclosure:** None reported.

**Correspondence:** Scott R. Steele, M.D., Cleveland Clinic Cleveland, 9500 Euclid Ave, A30, Cleveland, OH 44915. E-mail: [harkersteele@mac.com](mailto:harkersteele@mac.com)

Dis Colon Rectum 2019; 62: 146–157

DOI: 10.1097/DCR.0000000000001237

© The ASCRS 2019

## STATEMENT OF THE PROBLEM

Pilonidal disease is a potentially debilitating condition affecting ~70,000 patients annually in the United States alone.<sup>2</sup> Although there are conflicting etiological theories, the current consensus holds that pilonidal disease is an acquired condition intimately related to the presence of hair in the gluteal cleft.<sup>3</sup> Loose hairs trapped in the natal cleft traumatize and penetrate the skin, creating a foreign body reaction that may ultimately lead to formation of midline pits and, in some cases, secondary infection.<sup>4</sup> The spectrum of pilonidal disease presentation varies from a chronic cyst and/or sinus with persistent drainage and/or extensive subcutaneous tracts to the more acute presentation of an associated abscess. Numerous treatment options are available that include but are not limited to gluteal cleft hair removal, tract ablation, simple excision, and wide excision with flap reconstruction. This clinical practice guideline will focus on the evaluation and management of pilonidal disease.

## METHODOLOGY

PubMed was used to search MEDLINE for all of the entries included between November 1945 and November 2017 and limited to humans and English language. Search terms included the MEDLINE subject heading *pilonidal sinus* and the subheadings *anatomy/histology*, *diagnosis*, *diagnostic imaging*, *surgery*, and *therapy*, which provided 1022 titles. The PubMed search term *pilonidal abscess*, also with limitations to humans and English language, provided an additional 174 titles. One additional article was added after the initial search was completed. These 1197 titles (including Cochrane Systemic Database Reviews) were reviewed, duplicate references were resolved, and 1075 titles remained for initial review. Of these 1075 titles, 191 were excluded because of incorrect pub-

**TABLE 1.** The GRADE system: grading recommendations

Grade	Description	Benefit vs risk and burdens	Methodologic quality of supporting evidence	Implications
1A	Strong recommendation, high-quality evidence	Benefits clearly outweigh risk and burdens or vice versa	RCTs without important limitations or overwhelming evidence from observational studies	Strong recommendation, can apply to most patients in most circumstances without reservation
1B	Strong recommendation, moderate-quality evidence	Benefits clearly outweigh risk and burdens or vice versa	RCTs with important limitations (inconsistent results, methodologic flaws, indirect, or imprecise) or exceptionally strong evidence from observational studies	Strong recommendation, can apply to most patients in most circumstances without reservation
1C	Strong recommendation, low- or very low-quality evidence	Benefits clearly outweigh risk and burdens or vice versa	Observational studies or case series	Strong recommendation but may change when higher-quality evidence becomes available
2A	Weak recommendation, high-quality evidence	Benefits closely balanced with risks and burdens	RCTs without important limitations or overwhelming evidence from observational studies	Weak recommendation, best action may differ depending on circumstances or patient or societal values
2B	Weak recommendations, moderate-quality evidence	Benefits closely balanced with risks and burdens	RCTs with important limitations (inconsistent results, methodologic flaws, indirect, or imprecise) or exceptionally strong evidence from observational studies	Weak recommendation, best action may differ depending on circumstances or patient or societal values
2C	Weak recommendation, low- or very low-quality evidence	Uncertainty in the estimates of benefits, risks, and burdens; benefits, risks, and burdens may be closely balanced	Observational studies or case series	Very weak recommendation; other alternatives may be equally reasonable

Adapted from Guyatt G, Guterman D, Baumann MH, et al. Grading strength of recommendations and quality of evidence in clinical guidelines: report from an American College of Chest Physicians Task Force. *Chest*. 2006;129:174–181. Used with permission.

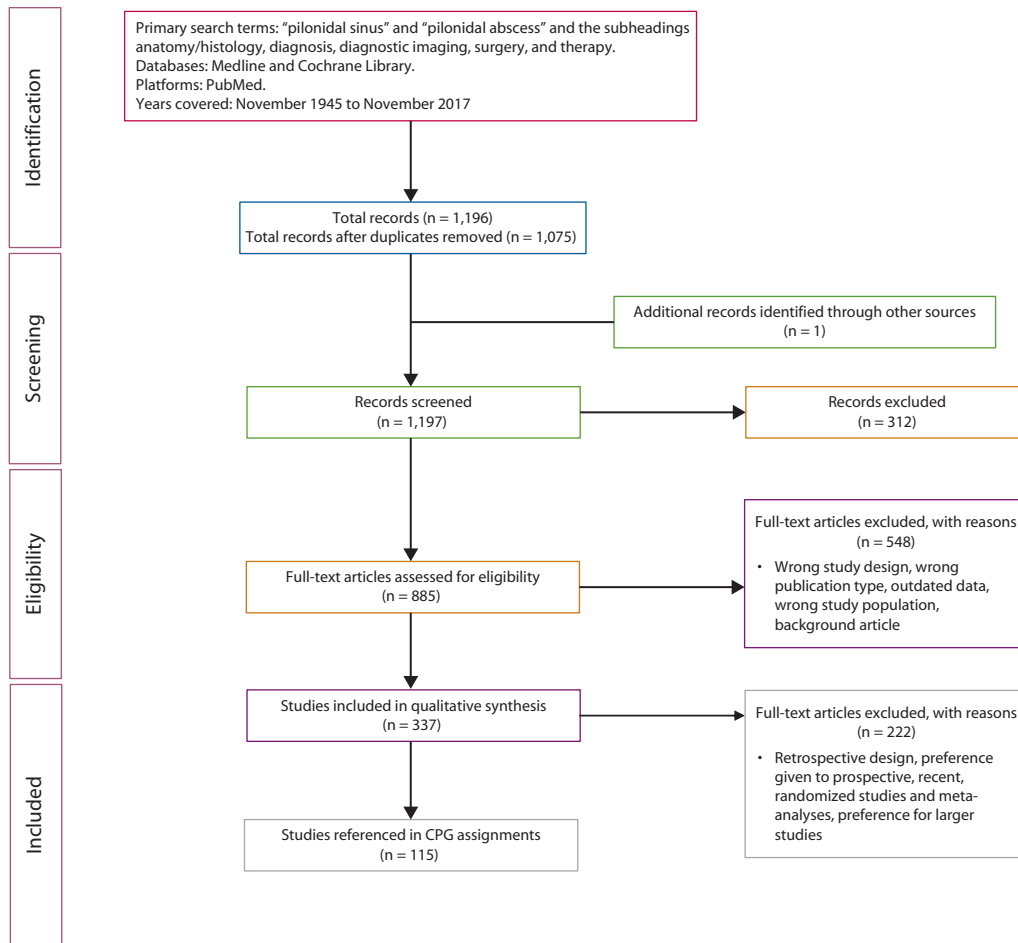
GRADE = Grades of Recommendation, Assessment, Development, and Evaluation; RCT = randomized controlled trial.

lication type (n = 27 titles) or subject matter (n = 164). This resulted in 885 unique references that were presented to the authors for additional review. Additional review resulted in exclusion of 548 titles because of  $\geq 1$  of the following reasons: wrong study design, wrong publication type, outdated data, wrong study population, or background article. The remaining 337 references were directly reviewed, ultimately yielding 115 references for inclusion (Fig. 1). Prospective, randomized controlled trials and meta-analyses were given preference in developing these guidelines. Directed searches of the embedded references from the primary articles were also performed in certain circumstances. The final source material used was evaluated for the methodologic quality, the evidence base was examined, and a treatment guideline was formulated by the subcommittee for this guideline. The final grade of recommendation was performed using the Grade of Recommendation, Assessment, Development, and Evaluation system<sup>1</sup> (Table 1). Members of the ASCRS Clinical Practice Guidelines Committee worked in joint production of these guidelines from inception to final publication. Recommendations formulated by the subcommittee were then reviewed by the entire Clinical Practice Guidelines Committee for edits and recommendations. Final recommendations were approved by the ASCRS Clinical Guidelines Committee and ASCRS Executive Committee. In general, each ASCRS Clinical Practice Guideline is updated every 3 to 5 years.

## INITIAL EVALUATION

1. A disease-specific history and physical examination should be performed, emphasizing symptoms, risk factors, and presence of secondary infection. **Grade of Recommendation: Strong recommendation based on low-quality evidence, 1C.**

The diagnosis of pilonidal disease is most often a clinical one, based on patient history and physical findings in the gluteal cleft, especially in patients with chronic or recurrent disease. However, it is important to distinguish pilonidal disease from alternative diagnoses, such as hidradenitis suppurativa, infected skin furuncles, Crohn's disease, perianal fistula, and infectious processes, including tuberculosis, syphilis, and actinomycosis.<sup>5</sup> On examination, those with pilonidal disease will almost always have characteristic midline pits in the gluteal cleft. In addition, although in the acute setting patients may present with cellulitis or a painful, fluctuant mass indicating the presence of an abscess, the chronic state is most often associated with chronic draining sinus disease in the intergluteal fold. Midline pits are often associated with subcutaneous tracts, most of which course cephalad, although some may course in a caudal direction and may be confused with anorectal fistulas. Special attention should be directed toward identification of concomitant cellulitis or an acute abscess to direct additional therapy. It is also important to perform a thorough anorectal examination to



**FIGURE 1.** A flow chart illustrating the search strategy for pilonidal disease. CPG, clinical practice guidelines.

evaluate for concomitant fistulous disease, Crohn's disease, or other anorectal pathology.<sup>5</sup> Although malignant degeneration of chronic pilonidal disease has been described, it is extremely rare but may be slightly more common in the immunosuppressed.<sup>6,7</sup> If skin lesions have a suspicious appearance, biopsy should be performed. Also, although not constituting a direct cause-and-effect relationship, risk factors associated with pilonidal disease include obesity, a sedentary lifestyle, repetitive trauma or irritation to the gluteal cleft skin, familial history of pilonidal disease, and a hirsute body habitus.<sup>2,3,8,9</sup> Identification of these traits may direct counseling or aid in promoting lifestyle modifications. A positive family history of pilonidal disease is a risk factor for disease and may be associated with a higher recurrence rate after surgery.<sup>10</sup> Adjunctive laboratory or radiological examinations are not routinely necessary.

## TREATMENT

### Nonoperative Therapy/ Nonoperative Adjuncts

1. Elimination of hair from the gluteal cleft and surrounding skin, by shaving or laser epilation, may be used for

both acute and chronic pilonidal disease in the absence of abscess as a primary or adjunct treatment measure. **Grade of Recommendation: Weak recommendation based on low-quality evidence, 1C.**

The rationale to support elimination of hair in the gluteal cleft relates to the significance of cleft hair in the development of pilonidal disease. Although it remains unclear whether the development of pilonidal disease is secondary to local pressure on the tissues, ruptured hair follicles, hypoxic tissue beds, or a congenital vulnerability of the natal skin, this central role of cleft hair in the pathogenesis has led to the expanded use of local shaving.<sup>4,11,12</sup> Shaving or laser epilation can serve as an adjunct treatment in active disease, as the sole agent of therapy, or as a preventative tool in the setting of chronic sinus disease to avoid recurrent flares and abscess formation.

Primary treatment of acute pilonidal disease, with limited lateral incision and drainage (I&D) or cyst excision, combined with surgeon-performed shaving along the intergluteal fold and surrounding region, promotes healing and prevents disease recurrence. Shaving should be repeated every 1 to 2 weeks until healing occurs and in combination with hygiene enforcement.<sup>13</sup> After exci-

sional procedures for chronic pilonidal disease, surgeon-performed hair shaving every 1 to 2 weeks until healing occurs and subsequent patient-performed shaving after healing occurs have also proven beneficial in preventing disease recurrence.<sup>14,15</sup> However, patient-performed shaving in the immediate postexcision period has been associated with an increase in pilonidal disease recurrence.<sup>16</sup>

Although this limits the ability to determine its exact contribution to overall healing, shaving is safe with, at most, minimal additional morbidity. While the most effective frequency and extent of shaving have yet to be clarified, we suggest at least weekly. When an abscess is present, this should be addressed surgically, although shaving can play an adjunctive role postoperatively, especially given the relative simplicity, potentially beneficial role, and limited downside to its use.

As an adjunct to surgical treatment, neodymium-doped yttrium aluminum garnet or alexandrite laser epilation has resulted in minimal ( $\leq 13\%$ ) recurrence of pilonidal disease.<sup>17–20</sup> When used as the primary treatment for initial or recurrent presentations of pilonidal disease, laser epilation has resulted in durable healing in 44% to 100% of patients who were treated in small, nonrandomized studies.<sup>21,22</sup> Laser epilation may require local anesthetic and often requires multiple treatments. The level and quality of evidence regarding this modality are insufficient to date to assess the significance or provide a general recommendation for this technique.

2. In patients with acute or chronic pilonidal disease without abscess, phenol application is an effective treatment that may result in rapid and durable healing. **Grade of Recommendation: Strong recommendation based on moderate-quality evidence, 1B.**

In addition to depilatory measures, other nonoperative techniques have been described for chronic pilonidal disease. The application of crystallized phenol to the cyst and tracts that are present in acute or chronic pilonidal disease has been performed in the outpatient setting, with local anesthesia, and has resulted in minor complications (infection and skin burns) in  $<15\%$  of patients, resolution of disease in 67% to 100% of patients, and elimination of recurrence in  $\geq 80\%$  of patients.<sup>23–28</sup> In general, the treatment procedure involves hair removal and curettage of the cyst and the application of 1 to 3 mL of crystallized phenol into the cyst and associated tracts. One to 4 procedures are most often required to achieve healing. In 1 retrospective study, laser epilation performed before phenol application resulted in 100% healing of pilonidal disease.<sup>29</sup> In a recent, randomized prospective trial of phenol treatment or surgical excision, with open healing or marsupialization, healing occurred in 100% of patients in each treatment group but more rapid healing, less pain, and faster return to normal activities in patients who underwent phenol treatment. In this study, pilonidal disease recurrence was observed in 19% and 13% of the phenol and surgery groups ( $p = 0.92$ ).<sup>28</sup> Even in the setting of recurrent chronic sinus disease, phenol injection and local depilatory

cream application on a weekly basis have shown low subsequent recurrence rates (0%–11%) at extended follow-up.<sup>30,31</sup>

3. In patients with chronic pilonidal disease without abscess, fibrin glue may be effective as a primary or adjunctive treatment of pilonidal disease. **Grade of Recommendation: Weak recommendation based on moderate-quality evidence, 2B.**

Similar to its role in perianal fistulas, fibrin glue has also been used in the setting of both chronic and recurrent pilonidal sinus disease. In multiple observational studies, fibrin glue or thrombin gelatin matrix has been used to fill the dead space and sinus tracts after pilonidal cyst excision and skin flap closure,<sup>32</sup> to fill the wound left by sinus excision without closure,<sup>33,34</sup> or to fill the voids left after curettage of pilonidal pits.<sup>35,36</sup> These series each included 6 to 50 patients with noninfected pilonidal disease and described healing at 2 to 6 weeks with infrequent minor complications and rare disease recurrence. Patient satisfaction with the fibrin glue procedure is high, and the majority are able to return to normal activities within 2 weeks of the procedure.<sup>37</sup> A randomized, prospective trial that included 32 patients with primary pilonidal disease, comparing the Limberg flap with or without fibrin glue under the flap, demonstrated that all of the patients in the fibrin group healed without evidence of recurrence at 8 months and had decreased wound drainage and hospital stay.<sup>38</sup> Another randomized prospective trial of 50 patients with primary pilonidal disease treated with a Karydakias flap with drain placement versus a Karydakias flap with fibrin glue under the flap demonstrated equal treatment efficacy, with healing in all of the patients but decreased hospital stay (2 vs 4 d), despite increased wound fluid collections (24% vs 8%), in the fibrin group.<sup>39</sup> Notwithstanding these favorable reports, a 2017 Cochrane review concluded that the evidence for benefit of fibrin glue in the treatment of pilonidal disease is uncertain.<sup>40</sup>

Regardless of the method used, the overriding goal of the nonoperative treatment strategy remains to remove all of the hair and debris that potentially act to potentiate a chronic low-grade inflammatory state, keeping the tract(s) open. After removal of the debris, the phenol or fibrin application eliminates granulation tissue and additional debris formation, allowing sinus closure. On closure, the importance of regular local hair removal techniques to ensure prevention of hair accumulation in the natal cleft remains. Unfortunately, a lack of overall and high-quality data makes it difficult to determine the exact roles that these therapeutic options will ultimately have in the management of this disease.

4. The value of prophylactic intravenous and topical prophylactic antibiotic in pilonidal disease surgery is not clear. Individualized consideration of their use is recommended. **Grade of Recommendation: Weak recommendation based on moderate-quality evidence, 2B.**



The use of antibiotics for pilonidal disease has been evaluated in 3 discrete situations: perioperative prophylaxis, postoperative treatment, and topical use. In the prophylactic role, 153 patients who underwent pilonidal excision and primary closure were prospectively randomly assigned to receive a single prophylactic dose of intravenous cefoxitin administered just before excision and primary closure versus no antibiotic; there were no benefits found with antibiotics in terms of wound infection prevention (32% vs 36%) or healing within 4 weeks (69% vs 64%).<sup>41</sup> In contrast, a large retrospective study of 131 patients reported that a single dose of intravenous prophylactic antibiotic was independently associated with a decreased surgical site infection rate after excision and primary closure for pilonidal disease.<sup>42</sup>

Perioperative administration of antibiotics may be beneficial. In a small, randomized, blinded study of patients undergoing primary closure, subjects received either a single-dose of prophylactic metronidazole or both cefuroxime and metronidazole preoperatively and 5 days of oral amoxicillin/clavulanic acid (Augmentin) postoperatively. The antibiotics cohort demonstrated significantly reduced wound infections in the antibiotic group at 4 weeks of follow-up (12% vs 44%).<sup>43</sup> Interestingly, no difference in wound healing was observed in a comparison of 1- and 4-day courses of perioperative metronidazole and ampicillin after excision and primary closure (77% vs 73%).<sup>44</sup>

In the postoperative setting, extended courses of antibiotics have shown mixed results, although large-scale data are lacking. As an adjunct to primary closure in chronic pilonidal disease comparing those left to heal by secondary intention, there were no differences in observed healing or recurrence rates once clindamycin was given postoperatively. Of the 3 groups, only secondary intention was associated with delayed healing.<sup>45</sup> On the other hand, the addition of metronidazole for 14 days or metronidazole with erythromycin after excision and secondary intention wound healing of a chronic pilonidal sinus tract showed a slightly shorter healing time in the antibiotic group compared with those without antibiotics.<sup>46</sup> Additional studies using longer durations of a variety of single- and double-coverage antibiotic regimens have failed to demonstrate any clear advantage.<sup>47</sup> In patients undergoing Rhomboid (Limberg) flap surgery for pilonidal disease, a recently reported prospective randomized trial of single-dose prophylactic cefazolin and metronidazole showed no benefit in terms of surgical site infection, duration of hospital stay, or disease recurrence as compared with no antibiotic prophylaxis.<sup>48</sup>

Limited and somewhat conflicting data currently exist on the use of topical antibiotic regimens in the treatment of pilonidal disease. One report demonstrated significantly higher wound-healing rates (86% vs 35%;  $p < 0.001$ ) after excision of chronic disease or previously drained acute pilonidal abscess and packing with an absorbable, gentamicin-impregnated, collagen-based

sponge with overlying primary wound closure than those without the antibiotic packing.<sup>49</sup> Unfortunately, the contributions of the gentamicin could not be separated from the potential role of the sponge material itself. A more recent study comparing primary closure over a gentamicin-soaked sponge versus secondary healing showed quicker healing and lower overall cost in the primary closure plus gentamicin group.<sup>50</sup> Another study investigating the effectiveness of the gentamicin sponge concluded that there was no benefit to closure over the sponge versus closure without it.<sup>51</sup> In a recently reported systematic review and meta-analysis, the use of a gentamicin collagen sponge resulted in a nonsignificant trend toward fewer wound infections and no significant influence on wound healing or disease recurrence.<sup>52</sup> Adjunctive use should be considered in the setting of severe cellulitis, underlying immunosuppression, or concomitant systemic illness despite limited evidence in this specific venue.<sup>4,53</sup>

### Operative Management

1. Patients with acute pilonidal disease characterized by the presence of an abscess should be treated with I&D regardless of whether it is a primary or recurring episode. **Grade of Recommendation: Strong recommendation based on moderate-quality evidence, 1B.**

*Acute pilonidal disease* is defined here as the presence of a pilonidal abscess with or without associated cellulitis. Although patients with chronic disease may acutely present with pilonidal sinus disease, an abscess in this setting presents with significant pain and tenderness, with an area of fluctuance and coexistent local cellulitis. As with any abscess, the mainstay of treatment is adequate surgical drainage, which involves creating an incision over the point of maximal fluctuance without addressing the midline pits. Overall successful healing reaches 60% when performing simple I&D for first-episode acute pilonidal abscesses; the remaining patients required a second definitive procedure to address excess granulation before wound closure.<sup>54</sup> Despite initial healing, simple I&D is associated with an estimated 15% to 40% recurrence rate, likely attributed to failure to address the underlying debris, epithelialization, granulation tissue, and sinus tracts that contribute to recurrence.<sup>55</sup> Regardless, I&D appears to have a protective effect on recurrence after surgical excision at 20-year follow-up,<sup>56</sup> underscoring its use in acute disease.

The roles that debris, inflammation, and granulation tissue play on recurrence and impaired wound healing are controversial. The unroofing (lay open) and curettage procedure is a 1-step option for pilonidal abscess that potentially avoids the need for a second procedure. In a randomized trial of acute abscesses undergoing I&D with or without curettage of the abscess cavity and removal of the inflammatory remains,<sup>57</sup> curettage was associated with significantly greater complete healing at 10 weeks (96% versus 79%;  $p =$

0.001) and lower incidence of recurrence <65 months post-operation (10% vs 54%;  $p < 0.001$ ). This was reinforced in a recent meta-analysis of the laying open and curettage technique, which demonstrated a low recurrence rate of 4.5% with a low complication rate of 1.4% and was successful in both acute and chronic pilonidal disease.<sup>58</sup>

The presence of active infection, acute abscess, in the setting of definitive pilonidal excision is thought to adversely affect wound healing and recurrence rates. However, although the data are limited, the use of local excision of both the abscess and the midline pits during the treatment of the acute pilonidal abscess, which allow healing by secondary intention as a way of eliminating all potential for future disease, has not been shown to alter recurrence rates, length of hospital stay, or overall time of healing.<sup>59</sup> There is limited evidence to suggest that patients treated with local excision of diseased tissue had a trend toward increased days off work (14 vs 7 d;  $p = 0.06$ ).<sup>59</sup> In an additional attempt to reduce the time to complete healing, delayed primary closure has been used after complete excision in the acute abscess. In a comparison of total excision of the acute pilonidal abscesses and pits with healing by secondary intention versus I&D of the abscess followed by delayed cyst excision and primary closure at 3 weeks,<sup>60</sup> there was no difference in disease recurrence between the 2 groups after 6 months, although 12-month follow-up demonstrated the primary closure group with a significantly higher recurrence rates (14% vs 0%;  $p < 0.05$ ). No difference was detected in wound infection or wound healing rates.

2. Patients who require surgery for chronic pilonidal disease may undergo excision and primary repair (with consideration for off-midline closure), excision with healing by secondary intention, or excision with marsupialization based on surgeon and patient preference. Drain use should be individualized. **Grade of Recommendation: Strong recommendation based on moderate-quality evidence, 1B.**

Surgical excision is the standard treatment for chronic pilonidal cyst and sinus disease and is generally divided into 2 categories: excision of diseased tissue with primary closure (including various flap techniques) versus excision with healing by secondary intention (including marsupialization). Comparing excision with primary midline closure versus excision with healing by secondary intention, there is a uniform significant trend toward faster median healing rates (range, 23–65 d) after primary closure in multiple prospective, randomized trials.<sup>50,61–63</sup> In addition, patients undergoing excision with healing by secondary intention had a longer time off from work compared with those undergoing excision with primary closure, regardless of closure method ( $\approx 10.48$  vs 5.75 d).<sup>61,62,64,65</sup> This is likely a result of not only faster healing but also a consequence of less pain and a decreased need for continued care with open wounds.

Despite these benefits, primary closure has certain drawbacks. Although high-volume case series using pri-

mary closure have demonstrated low recurrence rates of <6%,<sup>66</sup> this is generally not the case. Rather, as the 2010 Cochrane systematic review demonstrated, primary midline closure is associated with a significantly higher recurrence rate than after healing by secondary intention, with a recurrence rate of 8.7% after primary closure versus 5.3% with secondary intention. Overall, they found that healing by secondary intention reduced recurrence rates by 35% compared with primary closure.<sup>67</sup> Eleven individual studies, including 9 that directly compared midline primary closure with open healing, demonstrated an estimated 60% reduction in the risk of recurrent disease after healing by secondary intention when compared with primary closure after excision.<sup>45,61,62,64,68–72</sup> Interestingly, the surgical site infection rates between primary closure and those healed by secondary intention are similar, and wound infection of a primary closure incision does not contribute to long-term recurrence.<sup>73</sup>

Limited data are available directly comparing the efficacy of excision with marsupialization versus primary closure.<sup>70,74</sup> Primary closure was again shown to have improved healing times (range, 3–9 wk), whereas disease recurrence data were conflicting. One study<sup>74</sup> demonstrated similar rates in each group (4%–6%), whereas the other<sup>70</sup> reported significantly lower rates in the marsupialization group, occurring in 1.5% versus 17.0% after primary closure. Similar results demonstrating the lower recurrence rates with marsupialization, at the cost of slightly prolonged time to heal over primary closure, were reported in retrospective data comparing primary midline closure, healing by secondary intent, and marsupialization.<sup>14</sup> Additional results comparing marsupialization with wide local excision indicated that marsupialization was associated with significantly faster mean time to healing by a mean of 13 weeks, with lower complication and reoperative rates.<sup>75</sup> Comparatively, a randomized control trial of healing by secondary intention versus healing with negative-pressure wound therapy demonstrated no difference in time to complete wound healing, albeit in a small study population.<sup>76</sup>

The one principle that seems to provide a clear benefit is to close the wound off-midline, rather than direct midline when performing primary repair. This has consistently demonstrated faster healing times, lower rates of wound morbidity, and lower recurrence rates.<sup>77–80</sup> However, recurrence varies based on the primary closure procedure performed, with a recent meta-analysis demonstrating a higher recurrence rate (67%) in those with primary midline closure versus off-midline closure regardless of technique, with Bascom cleft-lift and Karydak flap with the lowest recurrence rate at any follow-up interval.<sup>81</sup> Unfortunately, this most often requires experience, skill, and comfort with performing flap-based procedures. Thus, we believe that it should remain up to the discretion of the surgeon and the patient to determine the risks and expected outcomes with each method before embarking on a single approach.

Drain use has been described after primary closure, both for removing effluent and irrigating the wound bed.<sup>82</sup> One nonrandomized study in chronic pilonidal disease found that drain placement after primary closure was associated with lower rates of complete wound dehiscence and faster rates of healing, although recurrence rates were similar.<sup>83</sup> Additional case series using mostly suction drains for 2 to 6 days after primary closure demonstrated low complication rates (0%–10%), with no morbidity directly attributed to the drain and a >85% rate of healing.<sup>82,84,85</sup> When used in conjunction with flap techniques, drains are associated with a decreased incidence in wound fluid collections but no difference in wound infections.<sup>86,87</sup> We recommend elective drain use on a case-by-case basis per surgeon preference.

3. Flap-based procedures may be performed, especially in the setting of complex and recurrent chronic pilonidal disease when other techniques have failed. **Grade of Recommendation: Strong recommendation based on moderate-quality evidence, 1B.**

In the setting of chronic pilonidal disease, often with previous surgical treatments, several flap-based treatment strategies have the goal of excising the disease while simultaneously providing healthy tissue coverage for the defect resulting from wide excision. With many techniques, soft-tissue reconstruction with the intent of altering the contour of the natal cleft as a measure to reduce additional disease recurrence has been attempted in both the primary and recurrent states.<sup>88</sup> Numerous flap techniques have been described, although discussion of each in detail goes beyond the scope of this guideline.

The rhomboid or Limberg flap, in which all of the affected skin and sinuses are excised to varying depth, with rotation of a lipocutaneous flap and closure that results in flattening of the gluteal cleft, has been used extensively in the treatment of refractory pilonidal disease. Overall results are favorable with respect to disease recurrence (0%–6%) and patient tolerance.<sup>77,78,89–91</sup> Potentially unfavorable points of this surgical procedure include a large area of tissue mobilization, increased risk of hematoma/seroma formation, and wound dehiscence.<sup>92</sup> Although data from several randomized trials found low (0%–6%) overall rates of surgical site infections,<sup>77,78,80</sup> a recent randomized controlled trial shows a very high rate of wound dehiscence associated with this type of flap.<sup>92</sup> Although many of these dehisces were minor, and the majority went on to heal without recurrence, they do require ongoing wound care. There are several relatively recent randomized trials that indicate either equivalence between various flap methods or an advantage of one flap over another in terms of disease recurrence, as well as short-term outcomes, such as wound dehiscence, quality of life, and patient satisfaction.<sup>91–98</sup>

The Karydakakis flap is an additional technique based on excision of diseased tissue from the midline with soft tissue

coverage in the form of a mobilized fasciocutaneous flap secured to the sacrococcygeal fascia with lateral suture lines to reduce recurrence in the midline. Karydakakis<sup>11</sup> reviewed his personal series of >6000 patients treated with this technique in 1992, with a recurrence rate <2% and wound complications in 8%. More recently, prospective nonrandomized data reported wound complications in 7% and recurrence in <1%.<sup>84</sup> Similar findings have been reported in case series using this technique (<5% recurrence; 9%–21% local complication rate),<sup>99,100</sup> with additional data demonstrating both smoking and obesity to be predictors of wound complications.<sup>101</sup> In randomized controlled studies comparing the Karydakakis procedure with open healing, the Karydakakis repair resulted in a 1.2% to 6.0% recurrence rate and 18.0% to 20.0% wound morbidity at a follow-up of 3 to 4 years.<sup>72,102</sup> These results were superior to the alternative of healing by secondary intention.

Similar to the Karydakakis procedure,<sup>11</sup> the cleft-lift technique aims to excise all diseased tissues with minimal removal of healthy tissue by creating a flap-based coverage off the midline, thus shallowing or lifting the natal cleft. Bascom and Bascom<sup>103</sup> reported successful healing in all patients in a series of 28 recurrent complicated pilonidal presentations. The follow-up study of 69 patients specifically with refractory pilonidal disease in nonhealing wounds reported a 96% healing rate.<sup>88</sup> Additional case series have confirmed these findings with healing rates of >80% to 97% in both the primary and recurrent settings.<sup>104–106</sup> Additional data have demonstrated the cleft-lift in the primary setting as well, with improved rates of healing and similar rates of recurrence as Bascom's other technique of lateral I&D with midline pit excision and closure.<sup>107</sup> A single randomized study showed improved short-term quality of life when the cleft-lift was compared with the Limberg flap.<sup>98</sup>

Several other flaps have been used for pilonidal disease, including the V-Y advancement and Z-plasty techniques, which are plastic surgical reconstruction patterns that have been used to provide tissue coverage for many different areas of the body. Minor wound complications, universal healing, and no disease recurrence have been reported in case series of patients managed with V-Y advancement,<sup>108</sup> although these results are likely not typical.

The Z-plasty technique has been described in numerous studies but with generally higher rates of wound complications and disease recurrence than the other flap methods. Prospective, randomized data comparing Z-plasty with excision with or without marsupialization demonstrated a significantly decreased need for additional surgical treatment after Z-plasty compared with healing by secondary intent.<sup>109</sup> Additional randomized data compared the Z-plasty with excision and secondary healing, demonstrating lower rates of surgical site infections, lower recurrence rates, and lower overall morbidity.<sup>68</sup> Regardless of which flap-based procedure is used, we believe that, before embarking on these techniques, surgeons should undergo additional



training to garner the expertise and experience required to achieve optimal outcomes. There is no large body of definitive evidence that supports the overall superiority of one flap technique over another. Surgeons must use judgment as to which technique applies best in any given situation, and that must be backed with appropriate training and experience in any technique applied.

4. Minimally invasive approaches to acute and chronic pilonidal disease that use endoscopic or video assistance may be used but require specialized equipment and expertise.  
**Grade of Recommendation: Weak recommendation based on moderate-quality evidence, 2B.**

In 2014, 2 pilot studies describing methods of minimally invasive treatment of pilonidal disease, endoscopic pilonidal sinus treatment and video-assisted ablation of pilonidal sinus (VAAPS), were published.<sup>110,111</sup> These initial results indicated a short-term recurrence rate of 0% to 3% at 6 to 12 months of follow-up and a rapid return to work or normal activities. The procedures are based on rigid endoscopic removal of hair and debris from all of the involved tracts with radiofrequency energy ablation of tissues within the tracts. This is done via the pits themselves, resulting in minimal incision size with minimal damage to adjacent tissue.

Both initial study groups followed up with larger trials. A prospective multicenter study of endoscopic pilonidal sinus treatment enrolled 250 patients with chronic disease and revealed a 94% healing rate by 26 days, with a 5% recurrence rate. Results were similar whether the procedure was performed as a primary or secondary intervention.<sup>112</sup> A randomized controlled trial comparing VAAPS with the Bascom cleft-lift procedure in 145 patients with follow-up of 12 months showed a faster time to return to work, as well as lower pain scores, fewer complications, lower infection rate, and increased patient satisfaction in the video-assisted group.<sup>113</sup> Interestingly, the authors did not report any long-term success rate or recurrence rate for either procedure, stating that a 12-month follow-up was too short from which to draw conclusions. A third group published a small prospective study on use of the VAAPS technique combined with the use of phenol, achieving a 100% success rate at 22 months of follow-up in 23 patients.<sup>114</sup>

Video-assisted techniques may prove to be effective over the long term but require specialized equipment and expertise. We lack large-scale definitive data on which to make definitive recommendations regarding the superiority of these techniques over any other.

### Management of Recurrent Pilonidal Disease

1. Operative strategies for recurrent pilonidal disease should distinguish between the presence of an acute abscess (section B1) and chronic disease (section B2), considering the experience and expertise of the surgeon. **Grade of Recommendation: Strong recommendation based on low-quality evidence, 1C.**

Recurrent and recalcitrant pilonidal disease continues to be a problem for both the patient and surgeon alike, and surgeons should be prepared to encounter this situation when managing this disease process. With a very wide rate of recurrence reported after initial intervention, as well as numerous described surgical procedures for treatment of disease, it may suffice to say there is a lack of a single optimal treatment strategy for primary pilonidal disease. Failures after secondary and tertiary procedures are seen as well, mandating effective treatment strategies for the management of recurrent disease. However, because recurrent presentations may herald a different problem, the surgeon needs to remain vigilant to exclude abnormal underlying etiologies of chronic perirectal pathology to include IBD, immunosuppression, and cutaneous neoplasms. In general, the goals and desires of the patient and experience and expertise of the surgeon will help guide management.

Although recurrence remains a common problem, as evidenced by the recurrence rates for various surgical procedures listed in these guidelines, there remains a relative paucity of evidence to directly guide the treatment of recurrent disease. Despite this drawback, therapy for the patient with recurrence in many aspects is similar to the de novo presentation. Proper hygiene, to include a trial of shaving, may remain a cornerstone in the outpatient management of recurrent disease. In addition, recurrent abscesses should be surgically drained as if they were sentinel presentations. In the face of nonacute recurrence or chronically recurring pilonidal sinus disease, the goal should be a treatment strategy that allows the patient to resume a normal lifestyle as quickly as possible.

Definitive flap-based procedures may be indicated if previous local excisions or multiple drainage procedures have been performed previously or if a minimally invasive approach may be entertained, with no strong evidence for either strategy. Randomized data that included only recurrent patients undergoing a modified asymmetric flap compared with a classical rhomboid flap demonstrated a lower wound infection rate (3% vs 23%), lower recurrence rate, shorter hospital stay, and faster return to work using the asymmetric flap.<sup>115</sup> Other randomized data including both de novo and recurrent patients likewise highlighted that success is feasible when using various flaps,<sup>70,79</sup> excision with primary closure, and excision with secondary intention methods<sup>45,71</sup> for these difficult patients. Thus, we recommend that patients be managed based on both the underlying presentation (ie, acute abscess, cellulitis, sinus, or subcutaneous tracts) and the goals, experience, and expertise of the surgeon. Although we lack specific evidence in the setting of pilonidal disease recurrence, it is recommended that known modifiable risk factors for surgical site occurrence, such as nutritional status, smoking cessation, glycemic control, and obesity, be optimized before embarking on repeat procedures.



## REFERENCES

- Schünemann HJ, Jaeschke R, Cook DJ, et al.; ATS Documents Development and Implementation Committee. An official ATS statement: grading the quality of evidence and strength of recommendations in ATS guidelines and recommendations. *Am J Respir Crit Care Med*. 2006;174:605–614.
- Søndena K, Andersen E, Nesvik I, Søreide JA. Patient characteristics and symptoms in chronic pilonidal sinus disease. *Int J Colorectal Dis*. 1995;10:39–42.
- da Silva JH. Pilonidal cyst: cause and treatment. *Dis Colon Rectum*. 2000;43:1146–1156.
- Hull TL, Wu J. Pilonidal disease. *Surg Clin North Am*. 2002;82:1169–1185.
- Steele SR, Hull TL, Read TE, et al. *The ASCRS Textbook of Colon and Rectal Surgery*, 3rd ed. New York, NY: Springer; 2016.
- de Bree E, Zoetmulder FA, Christodoulakis M, Aleman BM, Tsiatsis DD. Treatment of malignancy arising in pilonidal disease. *Ann Surg Oncol*. 2001;8:60–64.
- Malek MM, Emanuel PO, Divino CM. Malignant degeneration of pilonidal disease in an immunosuppressed patient: report of a case and review of the literature. *Dis Colon Rectum*. 2007;50:1475–1477.
- Bolandparvaz S, Moghadam Dizaj P, Salahi R, et al. Evaluation of the risk factors of pilonidal sinus: a single center experience. *Turk J Gastroenterol*. 2012;23:535–537.
- Arda IS, Güney LH, Sevmiş S, Hiçsönmez A. High body mass index as a possible risk factor for pilonidal sinus disease in adolescents. *World J Surg*. 2005;29:469–471.
- Doll D, Matevossian E, Wietelmann K, Evers T, Kriner M, Petersen S. Family history of pilonidal sinus predisposes to earlier onset of disease and a 50% long-term recurrence rate. *Dis Colon Rectum*. 2009;52:1610–1615.
- Karydakis GE. Easy and successful treatment of pilonidal sinus after explanation of its causative process. *Aust N Z J Surg*. 1992;62:385–389.
- Surrell JA. Pilonidal disease. *Surg Clin North Am*. 1994;74:1309–1315.
- Armstrong JH, Barcia PJ. Pilonidal sinus disease: the conservative approach. *Arch Surg*. 1994;129:914–917.
- Solla JA, Rothenberger DA. Chronic pilonidal disease: an assessment of 150 cases. *Dis Colon Rectum*. 1990;33:758–761.
- Al-Naami MY. Outpatient pilonidal sinotomy complemented with good wound and surrounding skin care. *Saudi Med J*. 2005;26:285–288.
- Petersen S, Wietelmann K, Evers T, Hüser N, Matevossian E, Doll D. Long-term effects of postoperative razor epilation in pilonidal sinus disease. *Dis Colon Rectum*. 2009;52:131–134.
- Badawy EA, Kanawati MN. Effect of hair removal by Nd:YAG laser on the recurrence of pilonidal sinus. *J Eur Acad Dermatol Venereol*. 2009;23:883–886.
- Lukish JR, Kindelan T, Marmon LM, Pennington M, Norwood C. Laser epilation is a safe and effective therapy for teenagers with pilonidal disease. *J Pediatr Surg*. 2009;44:282–285.
- Oram Y, Kahraman F, Karıncaoğlu Y, Koyuncu E. Evaluation of 60 patients with pilonidal sinus treated with laser epilation after surgery. *Dermatol Surg*. 2010;36:88–91.
- Schulze SM, Patel N, Hertzog D, Fares LG 2<sup>nd</sup>. Treatment of pilonidal disease with laser epilation. *Am Surg*. 2006;72:534–537.
- Landa N, Aller O, Landa-Gundin N, Torrontegui J, Azpiazu JL. Successful treatment of recurrent pilonidal sinus with laser epilation. *Dermatol Surg*. 2005;31:726–728.
- Khan MA, Javed AA, Govindan KS, et al. Control of hair growth using long-pulsed alexandrite laser is an efficient and cost effective therapy for patients suffering from recurrent pilonidal disease. *Lasers Med Sci*. 2016;31:857–862.
- Dogru O, Camci C, Aygen E, Girgin M, Topuz O. Pilonidal sinus treated with crystallized phenol: an eight-year experience. *Dis Colon Rectum*. 2004;47:1934–1938.
- Kaymakcioglu N, Yagci G, Simsek A, et al. Treatment of pilonidal sinus by phenol application and factors affecting the recurrence. *Tech Coloproctol*. 2005;9:21–24.
- Aygen E, Arslan K, Dogru O, Basbug M, Camci C. Crystallized phenol in nonoperative treatment of previously operated, recurrent pilonidal disease. *Dis Colon Rectum*. 2010;53:932–935.
- Dag A, Colak T, Turkmenoglu O, Sozutek A, Gundogdu R. Phenol procedure for pilonidal sinus disease and risk factors for treatment failure. *Surgery*. 2012;151:113–117.
- Olmez A, Kayaalp C, Aydin C. Treatment of pilonidal disease by combination of pit excision and phenol application. *Tech Coloproctol*. 2013;17:201–206.
- Calikoglu I, Gulpinar K, Oztuna D, et al. Phenol injection versus excision with open healing in pilonidal disease: a prospective randomized trial. *Dis Colon Rectum*. 2017;60:161–169.
- Girgin M, Kanat BH, Ayten R, et al. Minimally invasive treatment of pilonidal disease: crystallized phenol and laser depilation. *Int Surg*. 2012;97:288–292.
- Stephens FO, Sloane DR. Conservative management of pilonidal sinus. *Surg Gynecol Obstet*. 1969;129:786–788.
- Stansby G, Greatorex R. Phenol treatment of pilonidal sinuses of the natal cleft. *Br J Surg*. 1989;76:729–730.
- Greenberg R, Kashtan H, Skornik Y, Werbin N. Treatment of pilonidal sinus disease using fibrin glue as a sealant. *Tech Coloproctol*. 2004;8:95–98.
- Patti R, Angileri M, Migliore G, et al. Use of fibrin glue in the treatment of pilonidal sinus disease: a pilot study. *G Chir*. 2006;27:331–334.
- Seleem MI, Al-Hashemy AM. Management of pilonidal sinus using fibrin glue: a new concept and preliminary experience. *Colorectal Dis*. 2005;7:319–322.
- Lund JN, Leveson SH. Fibrin glue in the treatment of pilonidal sinus: results of a pilot study. *Dis Colon Rectum*. 2005;48:1094–1096.
- Elbanna HG, Emile SH, Youssef M, Thabet W, El-Hamed TM, Ghnnam WM. Novel approach of treatment of pilonidal sinus disease with thrombin gelatin matrix as a sealant. *Dis Colon Rectum*. 2016;59:775–780.
- Else E, Lund JN. Fibrin glue in the treatment for pilonidal sinus: high patient satisfaction and rapid return to normal activities. *Tech Coloproctol*. 2013;17:101–104.
- Altinli E, Koksall N, Onur E, Celik A, Sumer A. Impact of fibrin sealant on Limberg flap technique: results of a randomized controlled trial. *Tech Coloproctol*. 2007;11:22–25.
- Sözen S, Emir S, Güzel K, Ozdemir CS. Are postoperative drains necessary with the Karydakis flap for treatment of pilonidal sinus? (Can fibrin glue be replaced to drains?) A prospective randomized trial. *Ir J Med Sci*. 2011;180:479–482.
- Lund J, Tou S, Doleman B, Williams JP. Fibrin glue for pilonidal sinus disease. *Cochrane Database Syst Rev*. 2017;(1):CD011923.
- Søndena K, Nesvik I, Gullaksen FP, et al. The role of cefoxitin prophylaxis in chronic pilonidal sinus treated with excision and primary suture. *J Am Coll Surg*. 1995;180:157–160.

42. Popeskou S, Christoforidis D, Ruffieux C, Demartines N. Wound infection after excision and primary midline closure for pilonidal disease: risk factor analysis to improve patient selection. *World J Surg.* 2011;35:206–211.
43. Chaudhuri A, Bekdash BA, Taylor AL. Single-dose metronidazole vs 5-day multi-drug antibiotic regimen in excision of pilonidal sinuses with primary closure: a prospective, randomized, double-blinded pilot study. *Int J Colorectal Dis.* 2006;21:688–692.
44. Lundhus E, Gjøde P, Gottrup F, Holm CN, Terpling S. Bactericidal antimicrobial cover in primary suture of perianal or pilonidal abscess: a prospective, randomized, double-blind clinical trial. *Acta Chir Scand.* 1989;155:351–354.
45. Kronborg O, Christensen K, Zimmermann-Nielsen C. Chronic pilonidal disease: a randomized trial with a complete 3-year follow-up. *Br J Surg.* 1985;72:303–304.
46. Marks J, Harding KG, Hughes LE, Ribeiro CD. Pilonidal sinus excision–healing by open granulation. *Br J Surg.* 1985;72:637–640.
47. Mavros MN, Mitsikostas PK, Alexiou VG, Peppas G, Falagas ME. Antimicrobials as an adjunct to pilonidal disease surgery: a systematic review of the literature. *Eur J Clin Microbiol Infect Dis.* 2013;32:851–858.
48. Kundes MF, Cetin K, Kement M, et al. Does prophylactic antibiotic reduce surgical site infections after rhomboid excision and Limberg flap for pilonidal disease: a prospective randomized double blind study. *Int J Colorectal Dis.* 2016;31:1089–1091.
49. Vogel P, Lenz J. Treatment of pilonidal sinus with excision and primary suture using a local, resorbable antibiotic carrier: results of a prospective randomized study [in German]. *Chirurg.* 1992;63:748–753.
50. Rao MM, Zawislak W, Kennedy R, Gilliland R. A prospective randomised study comparing two treatment modalities for chronic pilonidal sinus with a 5-year follow-up. *Int J Colorectal Dis.* 2010;25:395–400.
51. Andersson RE, Lukas G, Skullman S, Hugander A. Local administration of antibiotics by gentamicin-collagen sponge does not improve wound healing or reduce recurrence rate after pilonidal excision with primary suture: a prospective randomized controlled trial. *World J Surg.* 2010;34:3042–3048.
52. Nguyen AL, Pronk AA, Furnée EJ, Pronk A, Davids PH, Smakman N. Local administration of gentamicin collagen sponge in surgical excision of sacrococcygeal pilonidal sinus disease: a systematic review and meta-analysis of the literature. *Tech Coloproctol.* 2016;20:91–100.
53. Hanley PH. Acute pilonidal abscess. *Surg Gynecol Obstet.* 1980;150:9–11.
54. Jensen SL, Harling H. Prognosis after simple incision and drainage for a first-episode acute pilonidal abscess. *Br J Surg.* 1988;75:60–61.
55. Fitzpatrick EB, Chesley PM, Oguntoye MO, Maykel JA, Johnson EK, Steele SR. Pilonidal disease in a military population: how far have we really come? *Am J Surg.* 2014;207:907–914.
56. Doll D, Evers T, Krapohl B, Matevossian E. Is there a difference in outcome (long-term recurrence rate) between emergency and elective pilonidal sinus surgery? *Minerva Chir.* 2013;68:199–205.
57. Vahedian J, Nabavizadeh F, Nakhaee N, Vahedian M, Sadeghpour A. Comparison between drainage and curettage in the treatment of acute pilonidal abscess. *Saudi Med J.* 2005;26:553–555.
58. Garg P, Menon GR, Gupta V. Laying open (deroofing) and curettage of sinus as treatment of pilonidal disease: a systematic review and meta-analysis. *ANZ J Surg.* 2016;86:27–33.
59. Matter I, Kunin J, Schein M, Eldar S. Total excision versus non-resectional methods in the treatment of acute and chronic pilonidal disease. *Br J Surg.* 1995;82:752–753.
60. Hosseini SV, Bananzadeh AM, Rivaz M, et al. The comparison between drainage, delayed excision and primary closure with excision and secondary healing in management of pilonidal abscess. *Int J Surg.* 2006;4:228–231.
61. Khawaja HT, Bryan S, Weaver PC. Treatment of natal cleft sinus: a prospective clinical and economic evaluation. *BMJ.* 1992;304:1282–1283.
62. Füzün M, Bakir H, Soylu M, Tansuğ T, Kaymak E, Hafmancioğlu O. Which technique for treatment of pilonidal sinus—open or closed? *Dis Colon Rectum.* 1994;37:1148–1150.
63. Søndena K, Nesvik I, Andersen E, Søreide JA. Recurrent pilonidal sinus after excision with closed or open treatment: final result of a randomised trial. *Eur J Surg.* 1996;162:237–240.
64. Søndena K, Andersen E, Søreide JA. Morbidity and short term results in a randomised trial of open compared with closed treatment of chronic pilonidal sinus. *Eur J Surg.* 1992;158:351–355.
65. McCallum IJ, King PM, Bruce J. Healing by primary closure versus open healing after surgery for pilonidal sinus: systematic review and meta-analysis. *BMJ.* 2008;336:868–871.
66. Montes O, Bagci M, Bilgin T, Coskun I, Ozgul O, Ozdemir M. Management of pilonidal sinus disease with oblique excision and primary closure: results of 493 patients. *Dis Colon Rectum.* 2006;49:104–108.
67. Al-Khamis A, McCallum I, King PM, Bruce J. Healing by primary versus secondary intention after surgical treatment for pilonidal sinus. *Cochrane Database Syst Rev.* 2010;(1):CD006213.
68. Fazeli MS, Adel MG, Lebaschi AH. Comparison of outcomes in Z-plasty and delayed healing by secondary intention of the wound after excision of the sacral pilonidal sinus: results of a randomized, clinical trial. *Dis Colon Rectum.* 2006;49:1831–1836.
69. Mohamed HA, Kadry I, Adly S. Comparison between three therapeutic modalities for non-complicated pilonidal sinus disease. *Surgeon.* 2005;3:73–77.
70. Gencosmanoglu R, Inceoglu R. Modified lay-open (incision, curettage, partial lateral wall excision and marsupialization) versus total excision with primary closure in the treatment of chronic sacrococcygeal pilonidal sinus: a prospective, randomized clinical trial with a complete two-year follow-up. *Int J Colorectal Dis.* 2005;20:415–422.
71. al-Hassan HK, Francis IM, Neglén P. Primary closure or secondary granulation after excision of pilonidal sinus? *Acta Chir Scand.* 1990;156:695–699.
72. Testini M, Piccinni G, Miniello S, et al. Treatment of chronic pilonidal sinus with local anaesthesia: a randomized trial of closed compared with open technique. *Colorectal Dis.* 2001;3:427–430.
73. Doll D, Matevossian E, Luedi MM, Schneider R, van Zypen D, Novotny A. Does Full wound rupture following median pilonidal closure alter long-term recurrence rate? *Med Princ Pract.* 2015;24:571–577.
74. Spivak H, Brooks VL, Nussbaum M, Friedman I. Treatment of chronic pilonidal disease. *Dis Colon Rectum.* 1996;39:1136–1139.
75. Tejirian T, Lee JJ, Abbas MA. Is wide local excision for pilonidal disease still justified? *Am Surg.* 2007;73:1075–1078.

76. Biter LU, Beck GM, Mannaerts GH, Stok MM, van der Ham AC, Grotenhuis BA. The use of negative-pressure wound therapy in pilonidal sinus disease: a randomized controlled trial comparing negative-pressure wound therapy versus standard open wound care after surgical excision. *Dis Colon Rectum*. 2014;57:1406–1411.
77. Abu Galala KH, Salam IM, Abu Samaan KR, et al. Treatment of pilonidal sinus by primary closure with a transposed rhomboid flap compared with deep suturing: a prospective randomised clinical trial. *Eur J Surg*. 1999;165:468–472.
78. Akca T, Colak T, Ustunsoy B, Kanik A, Aydin S. Randomized clinical trial comparing primary closure with the Limberg flap in the treatment of primary sacrococcygeal pilonidal disease. *Br J Surg*. 2005;92:1081–1084.
79. Berkem H, Topaloglu S, Ozel H, et al. V-Y advancement flap closures for complicated pilonidal sinus disease. *Int J Colorectal Dis*. 2005;20:343–348.
80. Ertan T, Koc M, Gocmen E, Aslar AK, Keskek M, Kilic M. Does technique alter quality of life after pilonidal sinus surgery? *Am J Surg*. 2005;190:388–392.
81. Stauffer VK, Luedi MM, Kauf P, et al. Common surgical procedures in pilonidal sinus disease: a meta-analysis, merged data analysis, and comprehensive study on recurrence. *Sci Rep*. 2018;8:3058.
82. Tritapepe R, Di Padova C. Excision and primary closure of pilonidal sinus using a drain for antiseptic wound flushing. *Am J Surg*. 2002;183:209–211.
83. Tocchi A, Mazzoni G, Bononi M, et al. Outcome of chronic pilonidal disease treatment after ambulatory plain midline excision and primary suture. *Am J Surg*. 2008;196:28–33.
84. Akinci OF, Coskun A, Uzunköy A. Simple and effective surgical treatment of pilonidal sinus: asymmetric excision and primary closure using suction drain and subcuticular skin closure. *Dis Colon Rectum*. 2000;43:701–706.
85. Serour F, Somekh E, Krutman B, Gorenstein A. Excision with primary closure and suction drainage for pilonidal sinus in adolescent patients. *Pediatr Surg Int*. 2002;18:159–161.
86. Gurer A, Gomceli I, Ozdogan M, Ozlem N, Sozen S, Aydin R. Is routine cavity drainage necessary in Karydakias flap operation? A prospective, randomized trial. *Dis Colon Rectum*. 2005;48:1797–1799.
87. Erdem E, Sungurtekin U, Neşşar M. Are postoperative drains necessary with the Limberg flap for treatment of pilonidal sinus? *Dis Colon Rectum*. 1998;41:1427–1431.
88. Bascom J, Bascom T. Utility of the cleft lift procedure in refractory pilonidal disease. *Am J Surg*. 2007;193:606–609.
89. Urhan MK, Küçükkel F, Topgul K, Ozer I, Sari S. Rhomboid excision and Limberg flap for managing pilonidal sinus: results of 102 cases. *Dis Colon Rectum*. 2002;45:656–659.
90. Topgül K, Ozdemir E, Kiliç K, Gökbayır H, Ferahköşe Z. Long-term results of limberg flap procedure for treatment of pilonidal sinus: a report of 200 cases. *Dis Colon Rectum*. 2003;46:1545–1548.
91. Sevinç B, Karahan Ö, Okuş A, Ay S, Aksoy N, Şimşek G. Randomized prospective comparison of midline and off-midline closure techniques in pilonidal sinus surgery. *Surgery*. 2016;159:749–754.
92. Käser SA, Zengaffinen R, Uhlmann M, Glaser C, Maurer CA. Primary wound closure with a Limberg flap vs. secondary wound healing after excision of a pilonidal sinus: a multicentre randomised controlled study. *Int J Colorectal Dis*. 2015;30:97–103.
93. Saydam M, Ozturk B, Sinan H, et al. Comparison of modified Limberg flap transposition and lateral advancement flap transposition with Burow's triangle in the treatment of pilonidal sinus disease. *Am J Surg*. 2015;210:772–777.
94. Bali İ, Aziret M, Sözen S, et al. Effectiveness of Limberg and Karydakias flap in recurrent pilonidal sinus disease. *Clinics (Sao Paulo)*. 2015;70:350–355.
95. Tokac M, Dumlu EG, Aydin MS, Yalcın A, Kilic M. Comparison of modified Limberg flap and Karydakias flap operations in pilonidal sinus surgery: prospective randomized study. *Int Surg*. 2015;100:870–877.
96. Arslan K, Said Kokcam S, Koksall H, Turan E, Atay A, Dogru O. Which flap method should be preferred for the treatment of pilonidal sinus? A prospective randomized study. *Tech Coloproctol*. 2014;18:29–37.
97. Bessa SS. Comparison of short-term results between the modified Karydakias flap and the modified Limberg flap in the management of pilonidal sinus disease: a randomized controlled study. *Dis Colon Rectum*. 2013;56:491–498.
98. Guner A, Boz A, Ozkan OF, Ileli O, Kece C, Reis E. Limberg flap versus Bascom cleft lift techniques for sacrococcygeal pilonidal sinus: prospective, randomized trial. *World J Surg*. 2013;37:2074–2080.
99. Kitchen PR. Pilonidal sinus: experience with the Karydakias flap. *Br J Surg*. 1996;83:1452–1455.
100. Petersen S, Aumann G, Kramer A, Doll D, Sailer M, Hellmich G. Short-term results of Karydakias flap for pilonidal sinus disease. *Tech Coloproctol*. 2007;11:235–240.
101. Al-Khayat H, Al-Khayat H, Sadeq A, et al. Risk factors for wound complication in pilonidal sinus procedures. *J Am Coll Surg*. 2007;205:439–444.
102. Keshvari A, Keramati MR, Fazeli MS, Kazemeini A, Meysamie A, Nouritaromlou MK. Karydakias flap versus excision-only technique in pilonidal disease. *J Surg Res*. 2015;198:260–266.
103. Bascom J, Bascom T. Failed pilonidal surgery: new paradigm and new operation leading to cures. *Arch Surg*. 2002;137:1146–1151.
104. Gendy AS, Glick RD, Hong AR, et al. A comparison of the cleft lift procedure vs wide excision and packing for the treatment of pilonidal disease in adolescents. *J Pediatr Surg*. 2011;46:1256–1259.
105. Senapati A, Cripps NP, Flashman K, Thompson MR. Cleft closure for the treatment of pilonidal sinus disease. *Colorectal Dis*. 2011;13:333–336.
106. Ortega PM, Baixauli J, Arredondo J, et al. Is the cleft lift procedure for non-acute sacrococcygeal pilonidal disease a definitive treatment? Long-term outcomes in 74 patients. *Surg Today*. 2014;44:2318–2323.
107. Nordon IM, Senapati A, Cripps NP. A prospective randomized controlled trial of simple Bascom's technique versus Bascom's cleft closure for the treatment of chronic pilonidal disease. *Am J Surg*. 2009;197:189–192.
108. Schoeller T, Wechselberger G, Otto A, Papp C. Definite surgical treatment of complicated recurrent pilonidal disease with a modified fasciocutaneous V-Y advancement flap. *Surgery*. 1997;121:258–263.
109. Hodgson WJ, Greenstein RJ. A comparative study between Z-plasty and incision and drainage or excision with marsupialization for pilonidal sinuses. *Surg Gynecol Obstet*. 1981;153:842–844.



110. Milone M, Musella M, Di Spiezio Sardo A, et al. Video-assisted ablation of pilonidal sinus: a new minimally invasive treatment—a pilot study. *Surgery*. 2014;155:562–566.
111. Meinero P, Mori L, Gasloli G. Endoscopic pilonidal sinus treatment (E.P.Si.T.). *Tech Coloproctol*. 2014;18:389–392.
112. Meinero P, Stazi A, Carbone A, Fasolini F, Regusci L, La Torre M. Endoscopic pilonidal sinus treatment: a prospective multi-centre trial. *Colorectal Dis*. 2016;18:O164–O170.
113. Milone M, Fernandez LM, Musella M, Milone F. Safety and efficacy of minimally invasive video-assisted ablation of pilonidal sinus: a randomized clinical trial. *JAMA Surg*. 2016;151:547–553.
114. Gecim IE, Goktug UU, Celasin H. Endoscopic pilonidal sinus treatment combined with crystalized phenol application may prevent recurrence. *Dis Colon Rectum*. 2017;60:405–407.
115. Cihan A, Ucan BH, Comert M, Cesur A, Cakmak GK, Tascilar O. Superiority of asymmetric modified Limberg flap for surgical treatment of pilonidal disease. *Dis Colon Rectum*. 2006;49:244–249.

## New Responsive Design website — optimized for mobile devices

Fuel Your Professional Growth at **dcrjournal.com**

**Diseases of the Colon & Rectum** has a new responsive design website that delivers an optimal reading experience on any mobile device – no app required! Access **DC&R** journal content on the go, plus these features:

- Podcasts
- Clinical Practice Guidelines Collection
- Visual Abstract Infographics
- Tips for Submitting to DC&R
- Video Introduction to each Issue from the Editor-in-Chief
- Video Abstracts and Video Vignettes
- Entire Archive of DC&R content back to 1958
- Links to Residents Corner and CME
- Legislative updates

Visit **dcrjournal.com** today.

Access is a subscriber and ASCRS member benefit.



7-R062

